

Case Report

Evaluation of a clavicle hook plate for fixation of unstable distal end comminuted clavicle fractures: Seven case reports

Chun-Kuan Lu^a, Feng-Chen Kao^{a,*}, Kuo-Yao Hsu^b, Chin-Hsien Wu^a, Cheng-Yo Yen^a, Yuan-Kun Tu^a^a Department of Orthopedic Surgery, E-Da Hospital, I-Shou University, Kaohsiung, Taiwan^b Department of Orthopedic Surgery, Chang Gung Memorial Hospital, Taipei, Taiwan

ARTICLE INFO

Article history:

Received 6 October 2010

Received in revised form

27 December 2010

Accepted 12 January 2011

Keywords:

comminution

Constant-Murley scores

distal clavicle

hook plate

unstable

ABSTRACT

We retrospectively evaluate the efficacy of a clavicle hook plate as a fixation device for unstable distal end comminuted clavicle fractures. Seven patients who visited our hospital between March 2004 and January 2009 were included in this study. The patients' age ranged from 26 years to 65 years, and the mean follow-up period was 6.9 months. All fractures were united, and there was no case of delayed union. There were no complications after surgery. At the final follow-up in January 2010, six excellent and one good Constant-Murley scores were noted. We conclude that the use of a hook plate is a reasonable option for fixation of an unstable distal end comminuted clavicle fracture, resulting in a high rate of union and satisfactory functional results.

Copyright © 2011, Taiwan Orthopaedic Association. Published by Elsevier Taiwan LLC. All rights reserved.

1. Introduction

Lateral clavicle fractures account for approximately 12–15% of all clavicle fractures, and unstable fractures are usually difficult to treat.¹ Neer^{2,3} subdivided these fractures into three categories. Neer Type 2 fractures are characterized by fractures medial to the coracoclavicular ligaments, with or without disruption of the coracoclavicle ligaments, and are unstable because of the displacing force that delays the bone union. The incidences of nonunion, delayed union, and malunion are high (22–35%)^{3–7} when they receive nonoperative treatments. Although the treatment for Neer Type 2 fractures is still controversial, most researchers recommend open reduction and internal fixation as the treatment of choice.^{1,7–13} However, a variety of other possible fixation methods, including tension-band wiring, Knowles pin fixation, coracoclavicular screw fixation, and plate fixation, are also available. Unfortunately, when the distal fragment is comminuted, rigid fixation and early mobilization are difficult to achieve. A hook plate (HP) with an extension under the acromion may be a useful fixation method for these specific fracture patterns.^{9,11} In the present study, we retrospectively reviewed the clinical outcomes of unstable distal end comminuted clavicle fractures fixed with a HP to

evaluate the bony union, range of motion (ROM), shoulder function, and rate of postoperative complications.

2. Materials and methods

Seven patients (5 men and 2 women) with isolated unstable distal end comminuted clavicle fractures who underwent Arbeitsgemeinschaft für Osteosynthesefragen clavicle-HP fixation at the E-DA Hospital between March 2004 and January 2009 were included in this study. We excluded patients with Neer Type 2 injuries with intact distal fragments and patients with acromioclavicular joint dislocations. Patients who were lost to follow-up and those with incomplete data were also excluded. The mean age of the patients at the time of surgery was 44 years (range, 26–65 years). The cause of injury was automobile accidents in four cases, motorcycle accidents in two cases, and a fall in one case. The right clavicle was involved in four cases and the left in three cases. All patients were treated within 7 days of injury.

The operative procedure was performed under general anesthesia with the patients on sitting position with the injured limb freely mobile. A standard sabre approach was used to expose and reduce the fracture. We preserved the soft tissue as much as possible and only the soft tissue above the clavicle was completely dissected. The hook was inserted into the soft tissue tunnel made in the subacromial space behind the acromioclavicular joint. If necessary, the plate was bent to conform to the clavicular shape. In our study, plate bending was necessary for six patients (85%).

* Corresponding author. Department of Orthopedic Surgery, E-Da Hospital, I-Shou University, No. 1, E-Da Road, Yan-Chau Shiang, Kaohsiung County 824, Taiwan. Tel.: +886 7 615 0011; fax: +886 7 615 0913.

E-mail address: harriet.fann@msa.hinet.net (F.-C. Kao).

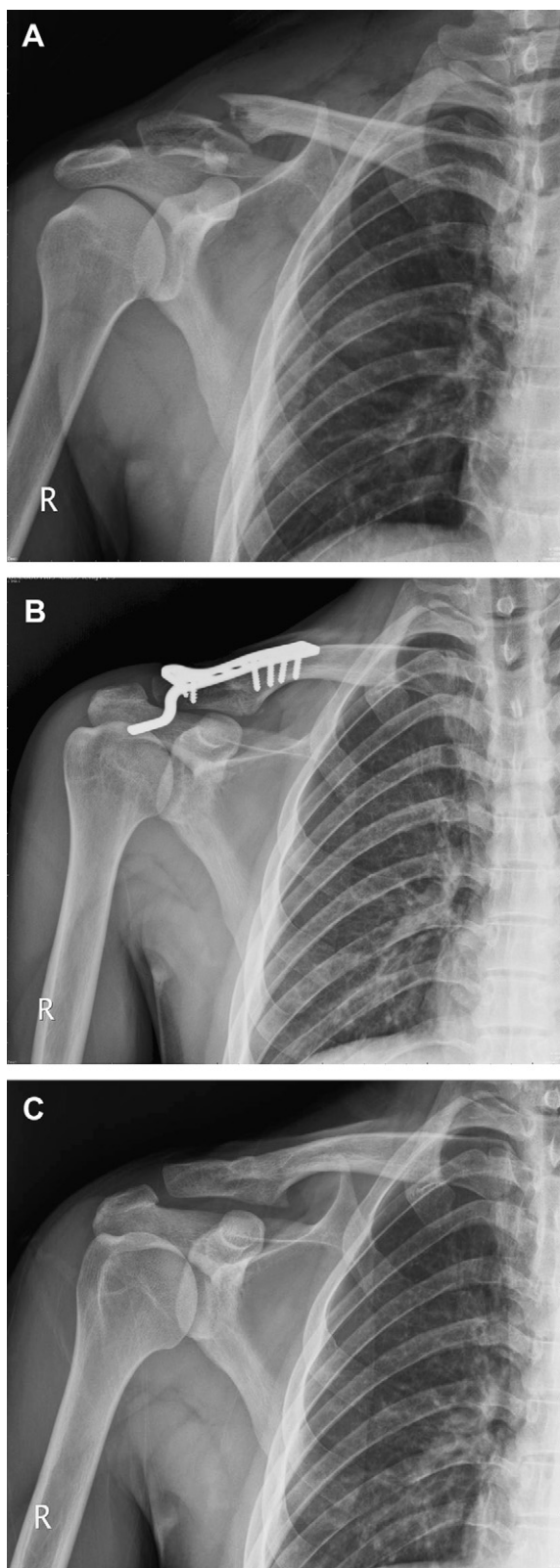


Fig. 1. (A) Twenty-six-year-old man with a right distal clavicle fracture caused by an automobile accident. Four fragments are noted over the distal end of the clavicle. (B) Postoperative X-ray showed that Hook plate fixation for Neer Type 2c fracture with adequate fixation and stability. (C) Good bone union (3 months postoperatively) after implant removal.

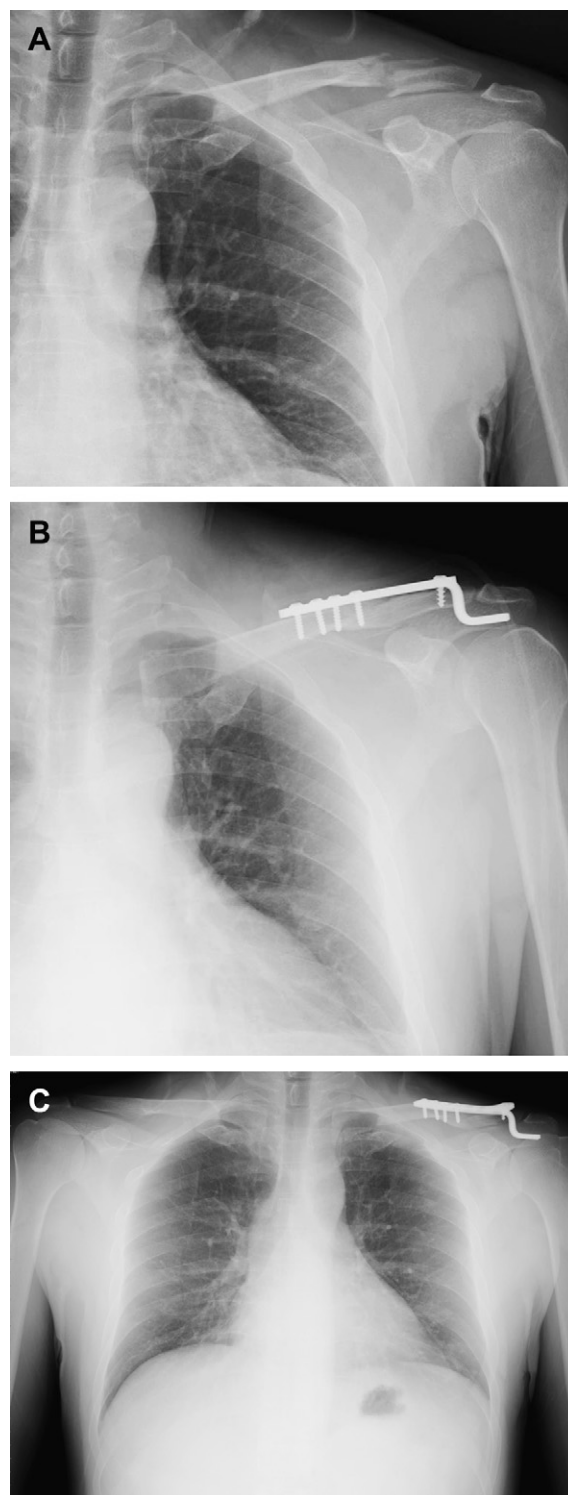


Fig. 2. (A) Forty-one-year-old woman with a left distal clavicle fracture caused by an accidental fall. A vertical split parallel to the shaft with three fragments over the distal end of the clavicle are noted. (B) Postoperative X-ray showed Hook plate fixation for Neer Type 2c fracture with adequate fixation and stability. (C) Good bone union (3 months postoperatively).

Pendulum exercises were performed by the patient from the second postoperative day. In all cases, the arm was supported by a sling for 6 weeks, during which overhead abduction and internal rotation of the shoulder behind the back were avoided. Mobilization was initiated as soon as possible, and only forward elevation of

the shoulder joint was encouraged after the operation until the implant was removed. After HP removal, full ROM exercises were recommended.

Heavy manual work was not allowed until the plate was removed. The average follow-up period from March 2004 to January 2010 was 6.9 months (range, 6–8 months). Plain radiographs were taken once every month to evaluate bone union. Fracture clinical union was defined here that the fracture site was painless. Radiographical union was defined as a bridged trabeculae across the fracture site or solid callus with cortical density connecting both fragments. At the final follow-up visit (2 months after HP removal), outcomes were evaluated using the Constant-Murley shoulder scoring system and the visual analog scale pain score.

3. Results

The fractures united uneventfully in all seven cases (Figs. 1 and 2). There was no case of delayed union or nonunion. The mean union time was 3.9 months. The mean duration from surgery until plate removal was 4.9 months (range, 4–6 months). Full ROM and shoulder function were restored in all patients. At the latest clinic follow-up visit (2 months after HP removal), the mean Constant-Murley score¹⁴ was 93.9 (range, 89–99). Constant-Murley scores are categorized as follows: excellent (90–100), good (80–89), satisfactory (70–79), and fair (<70); in our study, there were six excellent scores and one good score. The visual analog scale pain score of the injured side was 1.1 (range, 0–3) (Table 1). Furthermore, there were no postoperative complications.

4. Discussion

The treatment for Neer Type 2 fractures remains controversial. Nordqvist et al⁴ reported 22% nonunion of Neer Type 2 fractures in the nonoperative group, but most nonunions were clinically asymptomatic and no further operation was required. Robinson and Cairns⁶ also recommended nonoperative treatment for patients older than 35 years. But recently, most studies have reported excellent results and a high bone union rate for Neer Type 2 clavicle fractures using various fixation methods, such as tension-band wiring, Knowles pin fixation, coracoclavicular screw fixation, and plate fixation. However, most studies in the literature reported postoperative evaluations and assessment of Neer Type 2 injuries, with the exception of one study, which focused on Neer Type 2b injuries.¹⁵ According to Neer,^{2,3} a Type 2 injury is defined as a displaced fracture secondary to a fracture medial to the coracoclavicular ligament, and these can be further divided into two subgroups. In Type 2a injuries, the conoid and trapezoid ligament is attached to the distal clavicle, whereas in Type 2b injuries, the coracoclavicular ligament is detached from the medial fragment. Flinkkilä et al⁸ explained that the controversy over treatment for Neer Type 2 injuries may be because of the degree of displacement

of the fragments, and soft tissue injuries are not taken into account in the Neer fracture classification. In our study, we recognized a specific fracture pattern of Neer Type 2 fractures, which may differ from other subgroups, and have therefore introduced a new subgroup called “Neer Type 2c injury.” In Neer Type 2c fractures, the coracoclavicular ligament is detached from the medial fragment in addition to the presence of a comminuted distal fragment without acromioclavicular joint dislocation (Figs. 1 and 2A). As compared with other subgroups, vertical and horizontal instability is more likely to interfere with bone healing in Neer Type 2c fractures. A surgical approach for Neer Type 2c injuries should therefore provide stability and allow for early mobilization. However, it may be difficult to apply tension-band wiring, coracoclavicular screws, and Knowles pin fixation because the distal fragment is comminuted. In our study, HP fixation for Neer Type 2c fractures (Figs. 1 and 2B and C) achieved bone union and excellent or good clinical results.

Klein et al¹⁶ reported the results of fixation of Neer type 2 fractures using an HP and a superior locked plate with suture augmentation. Both fixation methods resulted in a high union rate (95% union rate in HP and 93.8% in superior locked plate with suture augmentation) and equal functional outcomes. Hermann et al¹⁵ also reported that the use of a locking T-plate osteosynthesis with suture anchor stabilization for unstable Neer Type 2b fractures resulted in good and excellent shoulder function and a 100% union rate. Thus, using a locking plate with interosseous sutures for Neer Type 2c fractures may be another good operational technique.

Although no complications were noted in our study, several drawbacks have been reported, and it is therefore important to exercise caution when using an HP. Impingement syndrome, peri-implantation failure, asymptomatic subacromial osteolysis, and rotator cuff tear have been reported by many authors.^{1,8,10,12,13,17,18} Kashii et al¹⁰ reported acromial fracture and hook cutout in 1 patient and widening of the hook hole in 19 of 34 patients who underwent HP fixation; these outcomes were mainly related to the hole that was drilled into the acromion for hook insertion. None of these complications were reported in studies in which the hook was inserted below the acromion, similar to the Arbeitsgemeinschaft für Osteosynthesefragen clavicle HP used in our study. Recently, ElMaraghy et al¹⁹ used cadaveric models for subacromial morphometric assessment of the clavicular HP. They noticed that despite the posterior orientation of the subacromial hook, the base of the hook still rested in the middle of the supraspinatus fossa. The occurrence of bursal inflammation in this space because of the presence of the subacromial hook could further narrow the distance between the supraspinatus tendon and the subacromial arch, predisposing patients to postoperative complications associated with rotator cuff impingement. We encouraged only forward elevation of the shoulder joint postoperatively until the implant was removed. After plate removal, full ROM exercise was recommended. In addition, to avoid impingement syndrome when using

Table 1
Patient demographics and clinical outcomes.

Patient	Sex	Age	Mec	Side injured	F/U (mo)	Evidence of union on X-ray (mo)	Plate removal (mo)	Constant score	VAS	Forward elevation of shoulder (degree)
1	M	26	AMA	Right	6	3	4	99	0	0–180
2	M	65	AMA	Right	8	5	6	93	1	0–180
3	M	57	MBA	Left	8	4	6	89	3	0–160
4	M	52	MBA	Right	6	4	4	93	1	0–180
5	F	38	AMA	Left	7	4	5	95	1	0–180
6	M	41	Fall	Left	6	3	4	95	1	0–180
7	F	29	AMA	Right	7	4	5	93	1	0–180

All fracture patterns were Neer Type 2b with distal comminuted fragment injuries.

AMA = automobile accident; F/U = follow-up; MBA = motorcycle accident; Mec = Mechanism; VAS = visual analog scale.

HP fixation, plate removal is required. Patients were routinely informed of this when fixation techniques were considered.

The main limitation of the present study is the small number of cases. In general, the incidence of unstable distal clavicle fractures is quite low, and herein, we further focused on “Neer Type 2c” fractures, which are even rarer. However, in our study, the results of HP fixation for this specific fracture pattern are promising.

In conclusion, we found that the use of a clavicle HP for the fixation of unstable distal end comminuted clavicle fractures resulted in union in 100% of cases and yielded good results with regard to function, early mobilization, and ROM, without any complications in our cases.

References

1. P.V. Meda, B. Machani, C. Sinopidis, I. Braithwaite, P. Brownson, S.P. Frostick. Clavicular hook plate for lateral end fractures: a prospective study. *Injury* 37 (2006) 277–283.
2. C.S. Neer 2nd. Fracture of the distal clavicle with detachment of the coracoclavicular ligaments in adults. *J Trauma* 3 (1963) 99–110.
3. C.S. Neer 2nd. Fractures of the distal third of the clavicle. *Clin Orthop Relat Res* 58 (1968) 43–50.
4. A. Nordqvist, C. Petersson, I. Redlund-Johnell. The natural course of lateral clavicle fracture. 15 (11–21) year follow-up of 110 cases. *Acta Orthop Scand* 64 (1993) 87–91.
5. A. Nordqvist, C. Petersson. The incidence of fractures of the clavicle. *Clin Orthop Relat Res* 300 (1994) 127–132.
6. C.M. Robinson, D.A. Cairns. Primary nonoperative treatment of displaced lateral fractures of the clavicle. *J Bone Joint Surg Am* 86 (2004) 778–782.
7. A.S. Rokito, J.D. Zuckerman, J.M. Shaari, D.P. Eisenberg, F. Cuomo, M.A. Gallagher. A comparison of nonoperative and operative treatment of type II distal clavicle fractures. *Bull Hosp Jt Dis* 61 (2002) 32–39.
8. T. Flinkkilä, J. Ristiniemi, M. Lakovaara, P. Hyvönen, J. Leppilahti. Hook-plate fixation of unstable lateral clavicle fractures: a report on 63 patients. *Acta Orthop* 77 (2006) 644–649.
9. T. Flinkkilä, J. Ristiniemi, P. Hyvönen, M. Hämäläinen. Surgical treatment of unstable fractures of the distal clavicle: A comparative study of Kirschner wire and clavicular hook plate fixation. *Acta Orthop Scand* 73 (2002) 50–53.
10. M. Kashii, H. Inui, K. Yamamoto. Surgical treatment of distal clavicle fractures using the clavicular hook plate. *Clin Orthop Relat Res* 447 (2006) 158–164.
11. Y.S. Lee, M.J. Lau, Y.C. Tseng, W.C. Chen, H.Y. Kao, J.D. Wei. Comparison of the efficacy of hook plate versus tension band wire in the treatment of unstable fractures of the distal clavicle. *Int Orthop* 33 (2009) 1401–1405.
12. K. Muramatsu, M. Shigetomi, T. Matsunaga, Y. Murata, T. Taguchi. Use of the AO hook-plate for treatment of unstable fractures of the distal clavicle. *Arch Orthop Trauma Surg* 127 (2007) 191–194.
13. A.D. Tambe, P. Motkur, A. Qamar, S.M. Turner. Fractures of the distal third of the clavicle treated by hook plating. *Int Orthop* 30 (2006) 7–10.
14. M. Tingart, H. Balthis, R. Lefering, B. Bouillon, T. Tiling. Constant score and Neer score. A comparison of score results and subjective patient satisfaction. *Unfallchirurg* 104 (2001) 1048–1054 [in German].
15. S. Herrmann, G. Schmidmaier, S. Greiner. Stabilisation of vertical unstable distal clavicular fractures (Neer 2b) using locking T-plates and suture anchors. *Injury* 40 (2009) 236–239.
16. S.M. Klein, B.L. Badman, C.J. Keating, D.S. Devinney, M.A. Frankle, M.A. Mighell. Results of surgical treatment for unstable distal clavicular fractures. *J Shoulder Elbow Surg* 19 (2010) 1049–1055.
17. R.M. Charity, S.G. Haidar, S. Ghosh, A.B. Tillu. Fixation failure of the clavicular hook plate: a report of three cases. *J Orthop Surg (Hong Kong)* 14 (2006) 333–335.
18. D.J.K.T. Edwards, M.C. Flannery. Fractures of the distal clavicle: a case for fixation. *Injury* 23 (1992) 44–46.
19. A.W. ElMaraghy, M.W. Devereaux, K. Ravichandiran, A.M. Agur. Subacromial morphometric assessment of the clavicle hook plate. *Injury* 41 (2010) 613–619.